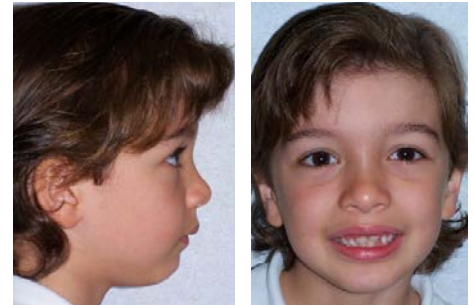

THEIR STORY SEBASTIAN

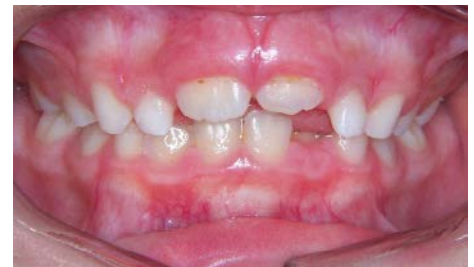as told by Dr. Juan-Carlos Quintero



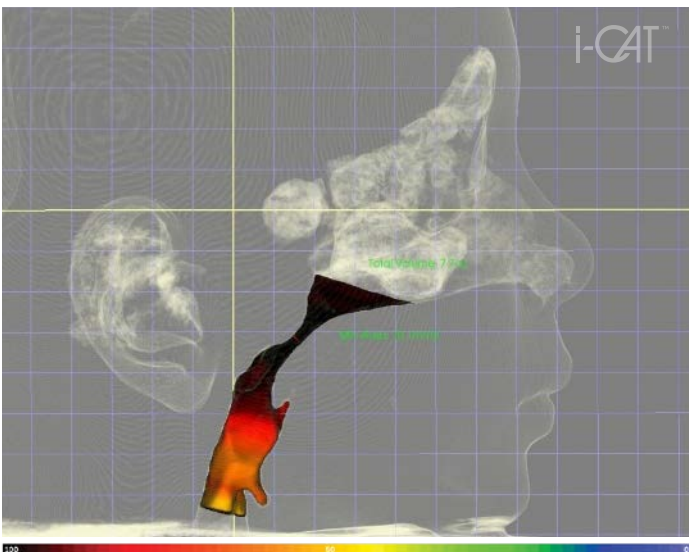
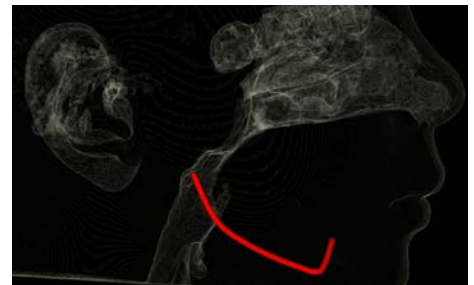
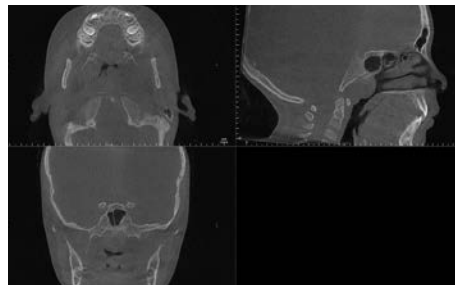
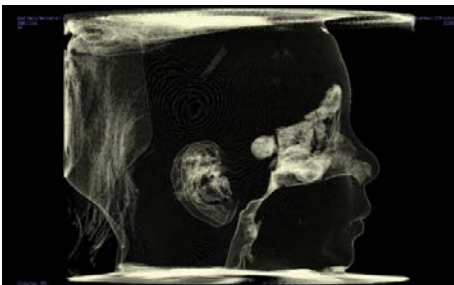
In the life of a practice, some patients create a lasting impression. When lives change for the better after successful treatment, it is not just a relief for the patient, but a time of reflection for the doctor. Such were my observations and experience with Sebastian, who at age 7 presented to my office with crowding and crooked teeth. At this early age, he already had other symptoms that, to me, signaled more serious health issues. With the help of 3D imaging, I pinpointed the problem and initiated positive action to improve this young man's life.



Sebastian had a history of mouth breathing, snoring, chronic fatigue, and allergies. He had already seen an array of medical specialists including ENTs, allergists, and pediatricians, but received no definitive diagnosis. At this point, I decided to take a low dose 3D scan with my i-CAT, not only to discern his overall dental-facial development and degree of crowding, but also to take a look at his anatomy, including airways, which a full-field-of-view i-CAT scan could provide.




These scans allow orthodontists like me to not just look at teeth, but I believe provide us with insight and visibility into part of a much greater craniofacial complex, with airways, bone, sinus and TMJ health all part of an integrated system. Although this vital anatomy has always been taken into account, now with the ability to see more structures in three dimensions, diagnosis and treatment planning takes on a whole new dimension because we can view all of this vital anatomy and not miss clues to unusual conditions.



I took a low-dose scan and captured the 3D volume. Mouth breathers can have suboptimal mandibular growth, and this 3D information helped me to understand some of the orthodontic problems, including why the mandible was not growing as favorably as it should have been at his age. In addition, to my surprise, I observed a very narrow airway with severe adenoid hypertrophy, enlarged turbinates, and sinus disease causing a significant airway obstruction and chronic facial inflammation. I was shocked to see an almost 100 percent obstruction at the level of his nasal pharynx due to his adenoids.

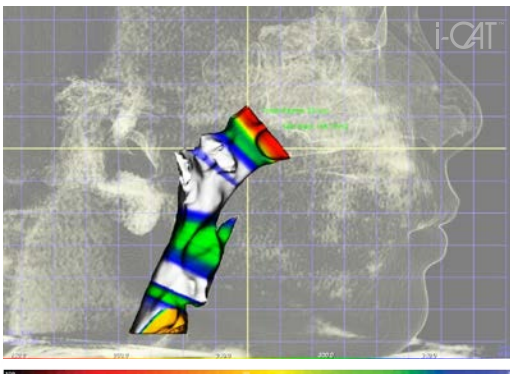
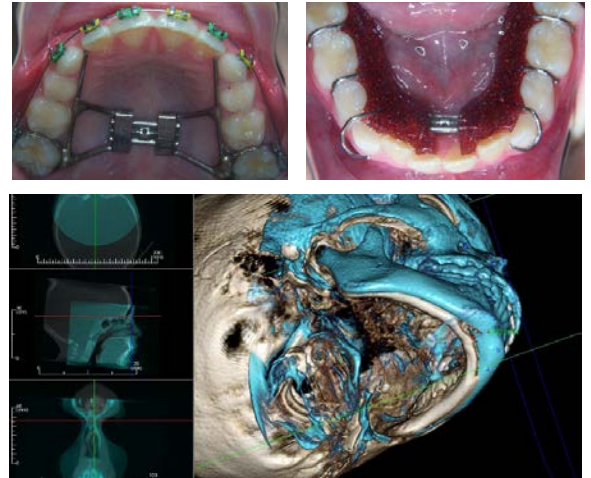
Continue →



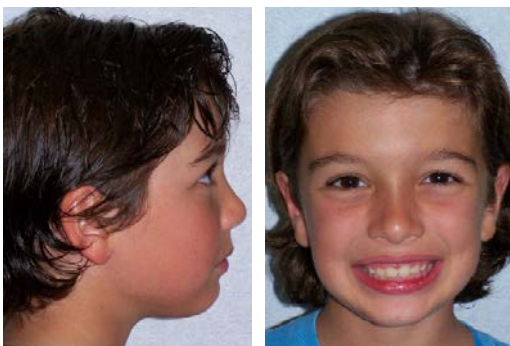as told by Dr. Juan-Carlos Quintero

Now that the diagnosis was established, it was easy to educate the patient and the medical team and set a collaborative course for treatment. The first thing I did was to promptly engage our ENT. I needed to act quickly to remove the adenoids. Sometimes, to get the ENT to address this type of problem, a parent has to be a bit forceful about the necessity to perform this procedure. Some ENTs opine, "Most kids outgrow these problems." While this may be true in some cases, it is also a fact that there is a critical window of facial growth during this age period that I feel we should not want to disrupt. As his orthodontist, I wanted to give him every opportunity to develop fully, and in my opinion, the airway needed to be managed first, including ENT surgery.

A treatment plan was developed and set in motion that included adenoidectomy, coblation of the turbinates, and orthodontic palatal expansion. Sebastian had the ENT procedures, followed by my rapid maxillary expansion at the level of craniofacial sutures which are still patent at this tender age of 7, not just to make room for his teeth, but to help promote better facial growth and adaptation and allow him to experience more favorable jaw growth. I also hoped to improve his airway through growth and development. Following removal of his adenoids, Sebastian received phase 1 interceptive orthodontic expansion treatment over the course of 10 months. After that, Sebastian just grew, for a year. After two years, I captured a post-treatment, low-dose scan to measure the results over time. I was able to measure the changes in his facial growth using the two scans by performing an automated voxel-based superimposition on the cranial base, which is a feature of the treatment planning software.



The results were dramatic. His airways actually grew; they were enlarged, and there was no longer an airway obstruction or blockage. The airway almost tripled in volume from 8 cc to 23 cc, and the smallest cross-sectional area (the bottleneck) went from 10 mm² to 304 mm². The obstruction was removed; the palatal shelf, being the floor of the nose, was expanded though Phase I orthodontic therapy; nasal breathing replaced predominant mouth breathing; the mandible was unlocked from its transverse discrepancy, and the vector of mandibular growth was redirected more horizontally. There is a recent study showing an increased incidence of TMJ Osteoarthritis on patients with environmental allergies.¹ In this case, I believe that the TMJs received less stress and, therefore, grew better due to the treatment Sebastian received for his issues described here.



The child's everyday life has also improved, and he is eating better, sleeping better, living better. Now, there is more room for the teeth to erupt, and the profile looks better. The color of his skin is improved, facial edema and inflammation have been eliminated, no more "droopy" eyes, and his smile looks great. He has improved alertness during the day and is more rested from more consistent sleep patterns. The parents also have observed no symptoms of sinus problems or allergies.

Continue →

THEIR STORY

SEBASTIAN

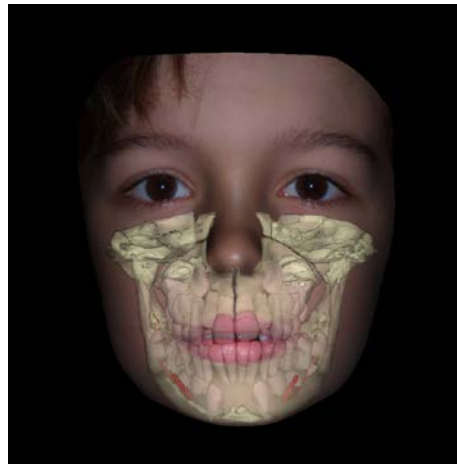
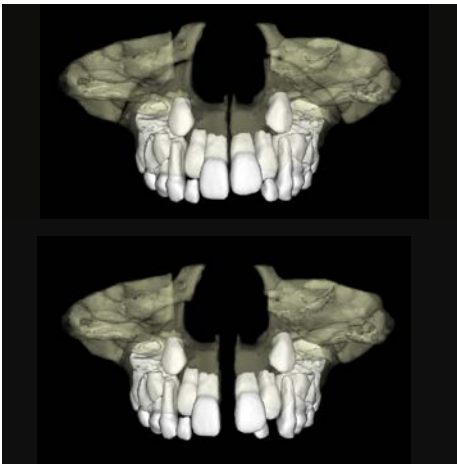
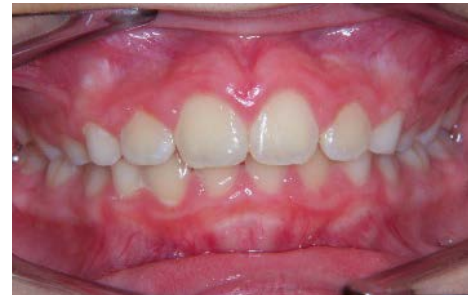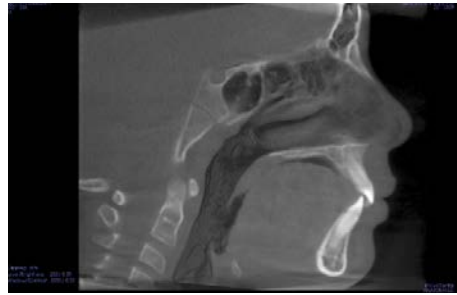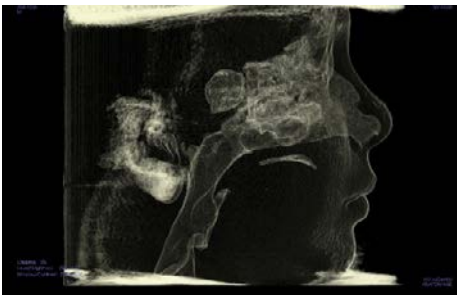as told by Dr. Juan-Carlos Quintero



The follow-up on Sebastian was easy — after all, he is my own son, and I can witness and celebrate his improvements on a daily basis. He is no longer tired or lethargic, and he has more energy. He can taste his food better, and now, instead of avoiding activity, he actually wants to play sports and is thriving in tennis.

This story illustrates the impact that orthodontists can have when we have the right tools to better visualize the anatomy and help create an individualized treatment plan. In my practice, Sebastian represents a landmark case that has forever changed the way I practice. CBCT imaging helped me to devise a plan to change his life, and in the long run, I will be empowered to provide treatment that can improve the lives of many other youngsters as well.



1 Nishioka M, Ioi H, Matsumoto R, Goto TK, Nakata S, Nakasima A, Counts AL, Davidovitch Z. TMJ osteoarthritis/osteoarthrosis and immune system factors in a Japanese sample. *Angle Orthod.* 2008;78(5):793-798.

The views and opinions expressed are those of Dr. Quintero and do not necessarily represent the views of i-CAT. The material is not intended to present the only, or necessarily best, methods or procedures for the medical situations addressed, but rather is intended to represent an approach, view, statement or opinion. Dr. Quintero has no financial interests in i-CAT, nor was he or his patient compensated for this article.